

Terina N. Martinez¹, Marco A. S. Baptista¹, Melanie A. Greeley², Mark T. Herberth², Daniel Kovarik¹, Adria Martig¹, Kuldip D. Dave¹, Mark A. Frasier¹, Brian Fiske¹, Todd Sherer¹

¹The Michael J. Fox Foundation for Parkinson's Research, ²WIL Research

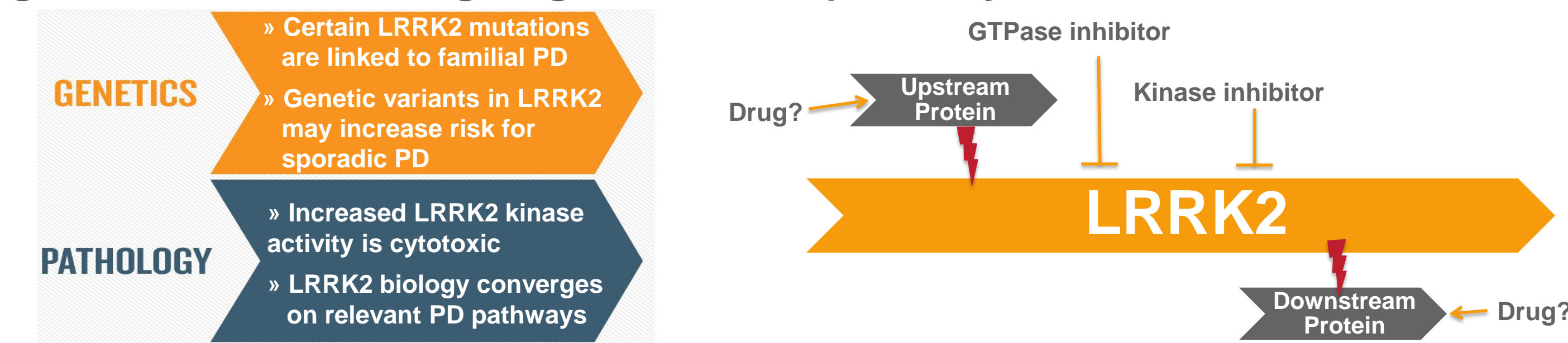Background

Several mutations in the gene leucine-rich repeat kinase 2 (*LRRK2*) are associated with autosomal-dominant late-onset Parkinson's disease (PD). The common G2019S mutation in the kinase domain increases *LRRK2* kinase activity and may partially explain *LRRK2*-related pathology. Thus, inhibition of *LRRK2* kinase activity is an attractive target for developing novel therapeutic approaches for PD patients. As part of a broad effort to determine the impact of loss of *LRRK2* function, which may be concomitant to pharmacological inhibition of *LRRK2* kinase activity, we undertook a rigorous study of histological and clinical pathology readouts in *LRRK2*-related mouse and rat models.

Outline of LRRK2 Rodent Pathology Studies:

- Pathology study comparing *LRRK2*^{-/-} to *LRRK2*^{+/+} rats at multiple ages (Baptista et al., 2013)
- Pathology study comparing *LRRK2*^{-/-} to *LRRK2*^{+/+} mice at multiple ages
- Pathology study in *LRRK2*^{-/-}, *LRRK2*^{+/-}, & *LRRK2*^{+/+} rats to assess gene dosage
- Histopathology pilot study in *LRRK1&2* double knockout rats at multiple ages

Figure 1. Rationale for Targeting LRRK2 Therapeutically

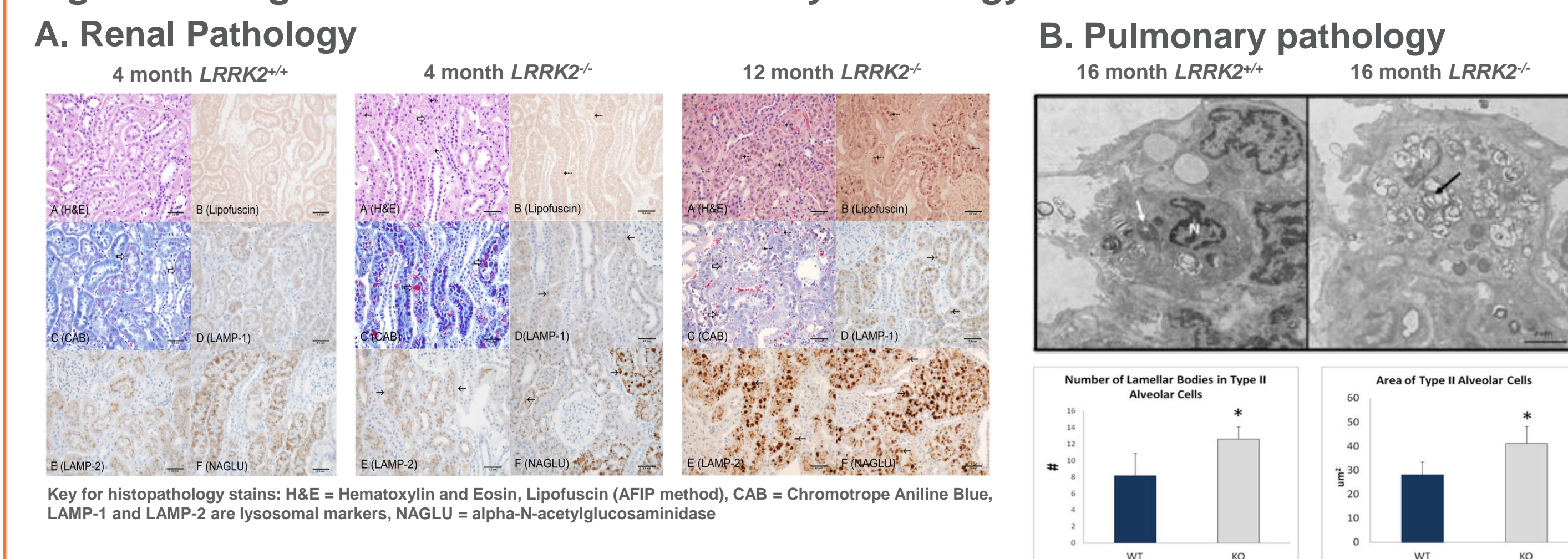


Pathology Study Comparing *LRRK2*^{-/-} to *LRRK2*^{+/+} Rats at Multiple Ages

Study Overview: Pathology was assessed in *LRRK2*^{-/-} and *LRRK2*^{+/+} Long Evans rats at several ages (1, 2, 4, 6, 8, 12, and 16 months of age)

Readouts: Hematology, serum chemistry, urinalysis, and microscopic evaluation (by histochemistry) of select organs, including lung and kidney

Figure 2. Progressive Renal and Pulmonary Pathology in *LRRK2*^{-/-} Rats



C. Summary of Pathology in *LRRK2*^{-/-} Vs. *LRRK2*^{+/+} Rats

Tissue/Organ System	Pathologic Observation	Age-related
Renal System	Nephropathy, cytoplasmic vacuolation, ↑ in brown pigment	Progressive, beginning at 2 mo.
Pulmonary System	Lamellar bodies in type II pneumocytes	Late-age onset (16 mo., by electron microscopy)
Clinical Pathology	↑ serum phosphate, creatinine, SDH, cholesterol ↓ serum Na ⁺ and Cl ⁻ levels	Some markers changed as early as 1 mo.
Urinalysis	↑ urine creatinine	Observed as early as 1 mo.
Hematology	No toxicologically relevant changes observed	N/A

Figure 2. Representative images of histopathologically stained kidney (cortex) sections from *LRRK2*^{-/-} or *LRRK2*^{+/+} rats at 4, or 12 months of age. *LRRK2*^{-/-} rats exhibited an unequivocal and age-progressive renal nephropathy associated with cytoplasmic vacuolation and accumulation of brown pigment (Figure 2A). Representative electron microscopy images of lung tissue from *LRRK2*^{-/-} or *LRRK2*^{+/+} rats at 16 months of age. Lung tissue from *LRRK2*^{-/-} rats exhibited an accumulation of Lamellar Bodies in Type II Alveolar Cells (Figure 2B). Summary of pathology findings in *LRRK2*^{-/-} versus *LRRK2*^{+/+} rats (Figure 2C). Clinical pathology, urinalysis, and hematology parameters were also assessed.

Pathology Study Comparing *LRRK2*^{-/-} and *LRRK2*^{+/+} Mice at Multiple Ages

Study Overview: Pathology was assessed in *LRRK2*^{-/-} and *LRRK2*^{+/+} mice (C57Bl/6J) at several ages (1, 2, 4, 8, and 12 months of age)

Readouts: Hematology, serum chemistry, urinalysis, and microscopic evaluation (by histochemistry) of select organs (including lung, kidney, and liver)

Figure 3. Assessment of Multiple Parameters of Pathology in *LRRK2*^{-/-} Mice

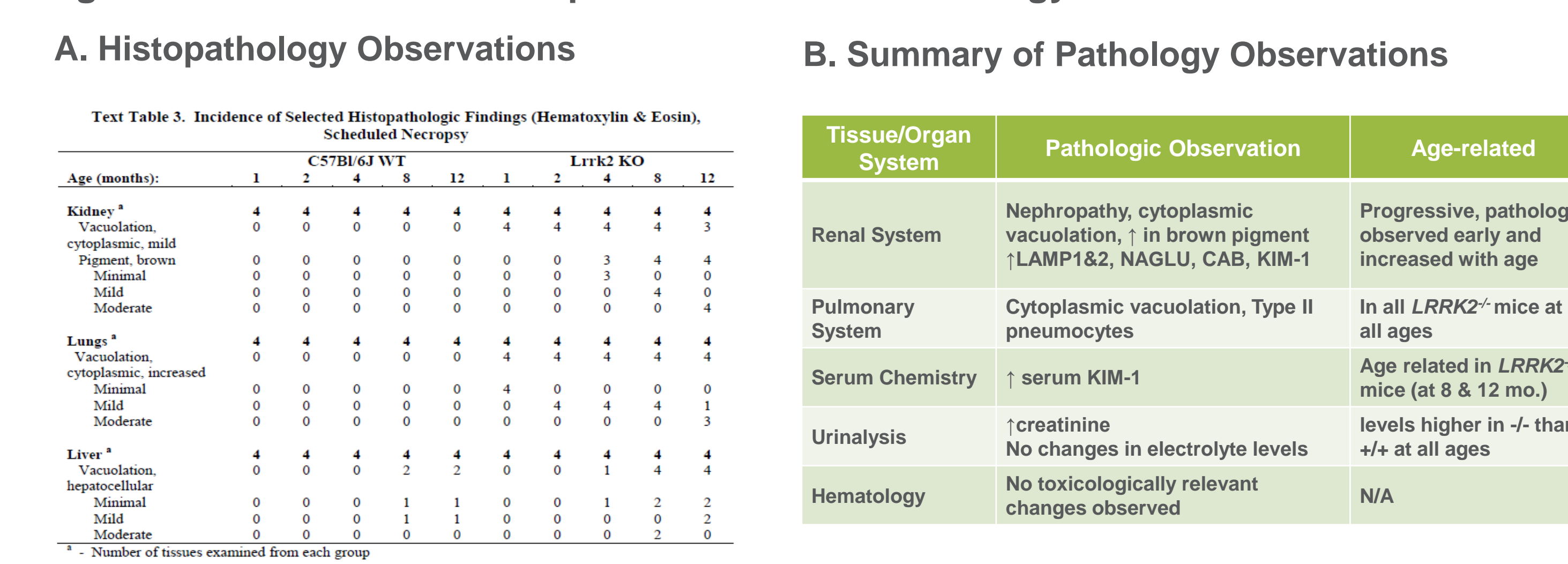


Figure 3. A histopathological assessment of kidney, lung, and liver pathology was performed in *LRRK2*^{-/-} and *LRRK2*^{+/+} mice at multiple ages (Fig. 3A). In addition to histopathological analysis of lung, liver, and kidney, additional readouts, including serum chemistry, urinalysis, and hematology were analyzed (Figure 3B). Kidney and lung pathology findings in *LRRK2*^{-/-} mice largely recapitulated previous observations in *LRRK2*^{-/-} rats, albeit with an apparent earlier age of onset in mice compared to rats. Notably, serum chemistry results indicated elevated levels of KIM-1 in *LRRK2*^{-/-} mice; KIM-1 was not detected by serum chemistry in *LRRK2*^{-/-} rats.

Pathology Study in *LRRK2*^{-/-}, *LRRK2*^{+/-}, and *LRRK2*^{+/+} Rats to Assess Gene Dosage

Study Overview: Pathology was assessed in *LRRK2*^{-/-}, *LRRK2*^{+/-}, and *LRRK2*^{+/+} rats (Long Evans) at 8 months of age

Readouts: Hematology, serum chemistry, urinalysis, and microscopic evaluation (by histochemistry) of select organs (lung, kidney, liver, heart, and spleen)

Figure 4. Assessment of *LRRK2*-related Gene Dosage Effects on Renal and Pulmonary Pathology

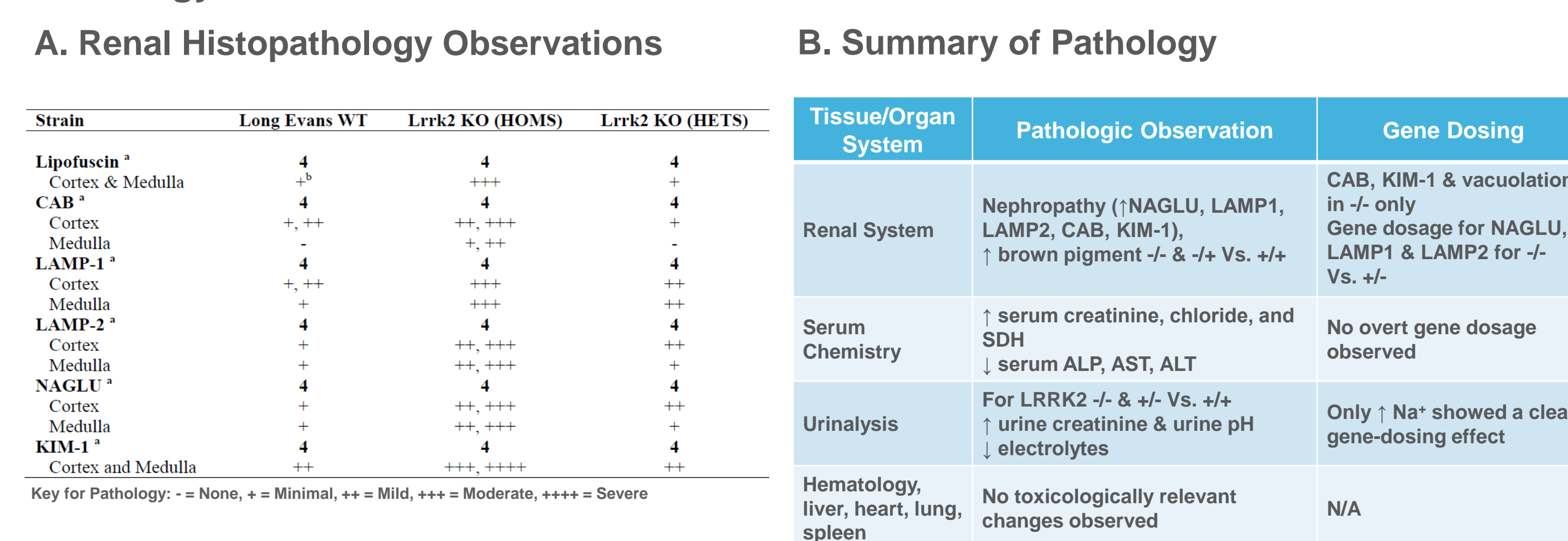


Figure 4. Kidney tissue from *LRRK2*^{-/-}, *LRRK2*^{+/-}, and *LRRK2*^{+/+} rats at 8 months of age was histopathologically analyzed (Figure 4A) using stains and protocols similar to those used in Figure 2. Figure 4B summarizes the pathology findings in this *LRRK2* gene-dosage study. An apparent gene-dosage effect for renal pathology with loss of *LRRK2* was observed. No pathologically-relevant differences in lung, liver, heart or spleen tissues were observed between the *LRRK2*^{-/-}, *LRRK2*^{+/-} or *LRRK2*^{+/+} groups. In the study described in Figure 2, lung pathology was observed in *LRRK2*^{-/-} rats, but only with advanced age (at 16 months).

Histopathology Pilot Study in *LRRK1&2* Double Knockout Rats at Multiple Ages

Objective: To assess potential *LRRK1* genetic interaction

Study Overview: Histopathology (via H&E staining) in kidney and lung tissue from *LRRK1&2* double KO rats versus WT rats at 4, 8, and 12 months of age

Methods: Light microscopic examination of H&E stained paraffin embedded sections from archived tissues from previous MJFF pathology studies at WIL Research. Sections from kidneys and lungs (including bronchi) were examined.

Figure 5. Summary of Histopathology Findings in *LRRK1&2* Double KO Rats

Tissue/Organ System	Pathologic Observation	Age-related
Renal System	Nephropathy; ↑ in brown pigment with cytoplasmic vacuolation	Progressive accumulation of brown pigment with age; also spread of vacuolation with age (cortex only at 4 mo., cortex & medulla 8 & 12 mo.)
Pulmonary System	No <i>LRRK1&2</i> double KO-related histological changes	N/A

Figure 5. The severity of chronic nephropathy in *LRRK1&2* double KO rats in this study appeared to be greater than what was observed in other pathology studies in *LRRK2*^{-/-} rats using similar methods.

Summary and Comparison of Pathology Observations in *LRRK2*-related Rodents

➤ Rat Studies:

- Progressive kidney pathology (nephropathy) associated with loss of *LRRK2*
- Evidence of a *LRRK2* gene dosage effect for kidney pathology
- Apparent exacerbation of *LRRK2*-related kidney pathology with loss of *LRRK1*
- Lung pathology (vacuolation in Type II pneumocytes) only with advanced age

➤ Mouse Studies:

- Pathology findings in *LRRK2*^{-/-} mice generally recapitulate observations in *LRRK2*^{-/-} rat models, although some species differences were observed
- Progressive kidney pathology (nephropathy) was associated with loss of *LRRK2*
 - Apparent earlier onset in mice compared to rats
- Lung pathology (Type II pneumocytes) was generally more severe in *LRRK2*^{-/-} mice than rats
- MJFF has not examined *LRRK2* gene dosage or potential effects of *LRRK1* in mice

Summary

Here we report recent pathology findings in *LRRK2*^{-/-} and *LRRK2*^{+/+} C57Bl/6 mice at several ages, *LRRK2* gene dosage effects in *LRRK2*^{-/-}, *LRRK2*^{+/-}, and *LRRK2*^{+/+} rats, and potential *LRRK1* genetic interaction in *LRRK1&2* double knockout versus wild type rats. Taken together, these pathology findings in *LRRK2*-related rodent models may inform follow-up studies aimed at therapeutic strategies to modulate *LRRK2* levels or kinase activity.

Reference: Baptista, M.A.S., Dave, K.D., Frasier, M.A., Sherer, T.B., Greeley, M., Beck, M.B., Varsho, J.V., Parker F.A., Moore, C., Churchill, M.J., Meshul, C.K., Fiske, B.F., *PLOS One*, 2013, PMID: 24244710;

Acknowledgements: All pathology studies in mice and rats were performed in partnership with WIL Research, Ashland, OH.